

JOSEPH A. JACHIMCZYK, M.D., J.D.

FORENSIC PATHOLOGIST
ATTORNEY AT LAW
CHIEF MEDICAL EXAMINER



854
E963

228-8311

EXT. 671 (DAY)
EXT. 212 (NIGHT)

OFFICE OF THE MEDICAL EXAMINER
OF HARRIS COUNTY

HARRIS COUNTY COURT HOUSE
HOUSTON, TEXAS 77002

AUTOPSY REPORT

Case 73 - 3333

August 9, 1973

PATHOLOGICAL DIAGNOSIS ON THE BODY

OF

Michael Anthony Baulch
439 West 16th Street
Houston, Texas


Gunshot wounds (2) of head, close range.

OPINION

It is our opinion that the decedent, Michael Anthony Baulch, came to his death as a result of gunshot wounds (2) of head, close range - Homicide.

It is our further opinion that death occurred on or about August 21, 1972.

COMMENT: In view of the above, it is our opinion, based upon a reasonable medical probability, these are the remains of Michael Anthony Baulch.


Joseph A. Jachimczyk, M.D., J.D.
Chief Medical Examiner

(See Companion Cases 73-3332, 73-3334, 73-3335, 73-3336, 73-3337, 73-3338, 73-3339, 73-3347, 73-3348, 73-3349, 73-3350, 73-3353, 73-3354, 73-3355, 73-3356 and 73-3357)

POSTMORTEM EXAMINATION ON THE BODY OF

Michael Anthony Baulch
439 West 16th Street
Houston, Texas

HISTORY: The body of this unidentified young male teenager (Unknown #2) was found at approximately 8:00 p.m. on August 8, 1973, in Stall #11, at 4500 Silverbell Street, Houston, Texas. (See Companion Cases 73-3332, 73-3334, 73-3335, 73-3336, 73-3337, 73-3338, 73-3339, 73-3347, 73-3348, 73-3349, 73-3350, 73-3353, 73-3354, 73-3355, 73-3356, and 73-3357)

AUTOPSY: The autopsy was performed by Chief Medical Examiner Joseph A. Jachimczyk, M.D., assisted by Assistant Medical Examiner Ethel E. Erickson, M.D., and assisted by Dr. Paul G. Stimson, beginning at 4:00 p.m. on August 9, 1973, in the Harris County Morgue.

EXTERNAL APPEARANCE: The body measured an approximate 70 inches in length and weighed a total of 70 pounds. The head was symmetrical and covered with light brown hair, measuring up to approximately 7 inches in length. Covering the eyes and face, there was heavy adhesive tape, and there was a mouth gag. The gag was a portion of Turkish towel. The facial features were not recognizable. The teeth were in a good condition. In the forehead, at a point 1 inch above the glabella, there was a gunshot entrance wound, the lumen of which measured .25 inches in diameter. In the right side of the head, there was another gunshot wound, just 1 inch above the right external ear. This wound measured 3/8 inch in diameter and had black discoloration on the surrounding bone. Each of the wounds had dark black charring on the bone. The neck was long, loose, flabby and thin. The thorax was symmetrical but fallen in, due to decomposition. The abdomen was scaphoid, also due to decomposition. Abundant fragments of cheesy material were over the anterior abdomen and anterior surfaces of the lower extremities. The upper extremities consisted only of wet bones. No hands were present. The feet were absent. The back was mostly deteriorated and partially eaten away with lime. Wrapped around the head, there was a blue plastic material tied with sash cord. There was also a loop of sash put around the chest. The skin of the chest and abdomen was parchment-like. The sagittal and coronal sutures of the skull were very sharply and clearly delineated.

INTERNAL EXAMINATION: Section: There were large defects in the lateral thorax and abdomen. The ribs were exposed. The costal chondral junctions were not calcified. The thoracic and abdominal viscera were largely decomposed and collapsed. The coronary arteries were smooth, thin, glistening and pliable. The remainder of the abdominal viscera were decomposed and partially destroyed with quick lime.

LUNGS: Only fragments of decomposed lung tissue remained.

LIVER: The liver weighed 300 grams. It was mostly decomposed.

BONES: There were no bony abnormalities, except for the missing bones and the two gunshot entrance wounds in the skull.

HEAD: The scalp was reflected in the usual coronal fashion. There were two separate bullet holes in the calvarium. Each of these was surrounded by a dark ring, extending $3/4$ inch. The lumen of the one in the right temporal bone measured $3/8$ inch in diameter, while that of the glabella measured .25 inches in diameter. The brain was soft and mushy. There were two misshapen .22 caliber bullets in the mushy brain, which weighed 150 grams. The base of the skull was intact.

A second series of skeletal X-rays were made following the autopsy and cleaning of the body. These films were made for the purpose of evaluation of bone age.

An anteroposterior view of the chest and shoulders showed all bones to be intact, including the spine, ribs, clavicles, and scapulae and humeri. The proximal ends of the humeri showed well defined epiphyseal plates, which were quite thin and centrally suggested scars of recent union. However, at the margins of the bone, there were small defects which indicate that fusion was incomplete. The distal ends of the humeri were not seen on this film. The proximal ends of the clavicles were visible. There was no evidence of a proximal clavicular epiphysis.

A film of the lower abdomen and pelvis included also a right ulna and the left ulna and radius. The radius appeared to be separated from the skeleton and was placed in inverted position. The proximal ends of the ulnas were not well visualized due to residual radio-opaque material, apparently lime.

The distal end of the left ulna showed an apparently unfused epiphysis. The epiphyseal plate was well visualized. The proximal radial epiphysis appeared to be fused. The distal radial epiphysis was not well visualized. The pelvis showed well defined calcified epiphyses of the iliac crests. The right was better visualized than the left, but neither crest appeared to be fused in any portion. The upper portions of both femurs were visible, but the degree of fusion could not be evaluated on this film.

An X-ray of the knees and portions of one foot comprised the third film. The foot was present as a separate specimen. The distal conjoint femoral epiphyses appeared to be fused, but the degree of fusion was not evaluable on this film. The proximal tibias showed what appeared to be a scar on epiphyseal union and the cortical outlines showed no visible defect. The proximal portions of both fibulae were visible, but the degree of epiphyseal fusion could not be evaluated.

Based upon the above information, the age of this decedent was estimated at 15 to 18 years.

DENTAL EXAMINATION

The Universal System is used. No fillings are present. Tooth number 1 is avulsed. The upper left and lower left and lower right third molars are impacted. There are caries as follows: occlusal caries in the upper right second molar, tooth number 2; there is attrition on the incisal edges of the upper right and left cuspids, teeth 6 and 11; there is occlusal caries on the lower left second molar, tooth 18; there is attrition on the incisal edges of the lower canines, which are teeth 22 and 27; there are occlusal caries on the lower right first and second molars, which are teeth 30 and 31. There is a chip on the incisal edge of tooth number 9, and a vertical crack on tooth number 8. The crack is approximately in the mid line. The jaw relationship is normal.

Paul G. Stimson

Paul G. Stimson, D.D.S., M.S.

Avulsed - 1
Impacted - 16, 17, 32
Occlusal Caries - 2, 18, 30, 31
Attrition - 6, 11, 22, 27
or incisal edges
Chip on incisal edge - 9
Vertical crack - # 8

u

SUPPLEMENTAL REPORT

October 8-9, 1973

Mrs. Baulch, together with Barbara Jo Cox, was at the Harris County Morgue between 9:30 a.m. and Noon on October 8, 1973, and was shown photographs of all of the clothing. She did not identify any items from the clothing on that day. Mr. Knowles, however, noticed a visible reaction when she looked at the silver belt buckle. She was then shown the hair display of the victims and said that Unknown #26 was similar to the hair of Billy, but Unknown #2 was too light to be similar to the hair of Michael. She was then shown three photographs of Unknown #2. She said she was unsure, but that it might be Michael. She was then shown the jaws of Unknown #2. She looked at them and stated that she could not be sure, but it could be Michael's mouth. Prior to this, however, she described a chip in tooth #9 and a vertical crack in tooth #8 on Michael.

She was then shown the maxilla of Unknown #26. When she saw the teeth in the anterior posterior view and then when the maxilla was being rotated so that she could have a headon look at the teeth numbers 8 and 9, she exclaimed "That's Billy's teeth" and broke into tears. After comforting her for approximately twenty minutes, we then asked her to look again at the maxilla and mandible of Unknown #2 and she said that that could be Michael, but she was not sure. She requested that her husband be permitted to see what she was shown this date. In fact, her niece, Barbara Jo Cox, called Mr. Baulch and spoke with him on the telephone. I also spoke with Mr. Baulch on the telephone and we made a date for him to come in with Mrs. Baulch between 8:00 and 8:30 a.m. on October 9, 1973.

Between 8:30 and 10:30 a.m. on October 9, 1973, Mr. Baulch was shown the same items. Initially, he thought that the hair of Unknown #2 was not quite coarse enough to be that of Michael, but that the hair of Unknown #26 could be Billy. He then looked at the photographs and he recognized the silver buckle and the belt to which it was attached as being his which he gave to Michael to wear. He was then shown the buckle and the belt, and he examined them very carefully, and both he and Mrs. Baulch agreed that that was the belt that Michael wore. Mrs. Baulch also stated how she cut the end of the

belt off to make it fit Michael. Mr. Baulch mentioned the stretching in the backside and demonstrated that. He demonstrated the sag in the backside of the belt and explained the reason for it happening, namely he being a truck driver sitting in that position for long intervals of time. He was then shown the same photographs of the Unknown #2 body taken during the autopsy and was not quite sure at that point whether it was Michael or not. He was then shown the maxilla of Billy first and he agreed with his wife's statement that this was Billy's mouth. He was then shown the maxilla and mandible of Unknown #2 and stated that that looked like it, but that he could not be positive immediately. He studied the teeth more fully. He, as well as Mrs. Baulch, remembered a crack in tooth #8, running the vertical length of the tooth. He related as to the manner of how he sustained that injury, when he jumped off and struck his chin against his knee and cracked his tooth. He also recognized the attrition resultant from the grinding habit that Michael was known to have. Both parents mentioned this even before we showed them the teeth. He then studied the smile by cupping his hands over the jawbones and looking only at the teeth and decided that yes that was Michael.

Finally, at their request, they were shown all of the autopsy photographs of Unknown #2, including the two gunshot holes, and at this point, each parent agreed it was Michael and that was Michael's hair. Accordingly, the body of Unknown #2, Michael, and the skeletal remains of Unknown #26, Billy Baulch, were made ready for release to the Heights Funeral Home, which was the wish of the parents. The funeral services were scheduled for 10:30 a.m. on October 12, 1973.

Mrs. Baulch also pointed out that the canines of Billy were real pointed and the canines on Michael were more worn and flat. This conforms to the appearance of these teeth in Unknown #2 and Unknown #26.

INVESTIGATOR'S REPORT

Autopsy

Investigator: L. C. Kelly

~~XVIEW~~

Case No. 73 - 3333

Decedent: Michael Anthony Baulch Race W Sex M Age 15

Address: 439 West 16th Street, Houston, Texas

Death: FOUND August 8, 1973 Approx. Time 8:00 ~~XXXX~~
P.M.

Place of Death: 4500 Silverbell Street, Stall #11, Houston, Texas

Place of Inquest: 4500 Silverbell Street, Stall #11, Houston, Texas

Date and Time of Inquest: August 8, 1973 8:45 ~~AMX~~
P.M.

Location, Position, and Surroundings of Body:

The decedent was lying in grave #1, wrapped in plastic, lying on the left side under Unknown #1.

Clothing: There was no clothing.

Information:

This is a related case to Medicolegal 73-3329.

L. C. Kelly
L. C. Kelly *LN*

(See Companion Cases 73-3332, 73-3334, 73-3335, 73-3336, 73-3337, 73-3338, 73-3339, 73-3347, 73-3348, 73-3349, 73-3350, 73-3353, 73-3354, 73-3355, 73-3356 and 73-3357)

Property: There was no property.

Transferred to Morgue by: Bob Lee Funeral Home, Houston, Texas

Funeral Home Conducting Service: Heights Funeral Home, Houston, Texas

CERTIFICATE OF DEATH

STATE FILE NO.

STATE OF TEXAS

1. PLACE OF DEATH a. COUNTY HARRIS		2. USUAL RESIDENCE (Where deceased lived. If institution: residence before admission) a. STATE TEXAS b. COUNTY HARRIS	
b. CITY OR TOWN (If outside city limits, give precinct no.) Houston		c. CITY OR TOWN (If outside city limits, give precinct no.) Houston	
d. NAME OF (If not in hospital, give street address) HOSPITAL OR INSTITUTION (found) 4500 Silverbell, Stall #11		d. STREET ADDRESS (If rural, give location) 439 West 16th	
e. IS PLACE OF DEATH INSIDE CITY LIMITS? YES <input type="checkbox"/> NO <input type="checkbox"/>		e. IS RESIDENCE INSIDE CITY LIMITS? YES <input checked="" type="checkbox"/> NO <input type="checkbox"/>	
f. IS RESIDENCE ON A FARM? YES <input type="checkbox"/> NO <input checked="" type="checkbox"/>		4. DATE OF DEATH Found 8-8-73	
3. NAME OF DECEASED (Type or print) (a) First MICHAEL (b) Middle ANTHONY (c) Last BAULCH		5. SEX Male	
6. COLOR OR RACE White		7. Married <input type="checkbox"/> Never Married <input checked="" type="checkbox"/> Widowed <input type="checkbox"/> Divorced <input type="checkbox"/>	
8. DATE OF BIRTH Aug. 8, 1957		9. AGE (In years last birthday) 15	
10a. USUAL OCCUPATION (Give kind of work done during most of working life, even if retired) Student		10b. KIND OF BUSINESS OR INDUSTRY School	
11. BIRTHPLACE (State or foreign country) Houston, Texas		12. CITIZEN OF WHAT COUNTRY? USA	
13. FATHER'S NAME Billy Baulch Sr.		14. MOTHER'S MAIDEN NAME Maggie Jane Cox	
15. WAS DECEASED EVER IN U.S. ARMED FORCES? (Yes, no, or unknown) No (If yes, give war or dates of service)		16. SOCIAL SECURITY NO.	
17. INFORMANT		18. CAUSE OF DEATH [Enter only one cause per line for (a), (b), and (c).] PART I. DEATH WAS CAUSED BY: IMMEDIATE CAUSE (a) Gunshot wounds (2) of head, close range. DUE TO (b) _____ DUE TO (c) _____ Conditions, if any, which gave rise to above cause (a), stating the underlying cause last: _____	
PART II. OTHER SIGNIFICANT CONDITIONS CONTRIBUTING TO DEATH BUT NOT RELATED TO THE TERMINAL DISEASE CONDITION GIVEN IN PART I(a)		19. WAS AUTOPSY PERFORMED? YES <input checked="" type="checkbox"/> NO <input type="checkbox"/>	
20a. ACCIDENT <input type="checkbox"/> SUICIDE <input type="checkbox"/> HOMICIDE <input checked="" type="checkbox"/>		20b. DESCRIBE HOW INJURY OCCURRED. (Enter nature of injury in Part I or Part II of Item 18.) Shot.	
20c. TIME OF INJURY Hour _____ Month _____ Day _____ Year _____ a.m. _____ p.m. 8 8 73		20d. INJURY OCCURRED WHILE AT WORK <input type="checkbox"/> NOT WHILE AT WORK <input checked="" type="checkbox"/>	
20e. PLACE OF INJURY (If at home, give street, office building, etc.) (found) #11 4500 Silverbell, Stall/		20f. CITY, TOWN, OR LOCATION COUNTY STATE Houston Harris Texas	
21. I hereby certify that I attended the deceased from found to _____, 19____ and last saw the deceased alive on from autopsy findings Death occurred at 8-8-73 m. on the date stated above and to the best of my knowledge, from the causes stated.		22a. SIGNATURE (Degree of title) Joseph A. Jachimczyk, M.D.	
22b. ADDRESS 209 Courthouse Houston, Texas		22c. DATE SIGNED 10-17-73	
23a. BURIAL, CREMATION, REMOVAL (Specify) Burial		23b. DATE October 12, 1973	
23c. NAME OF CEMETERY OR CREMATORY Woodlawn Garden of Memories		24. FUNERAL DIRECTOR'S SIGNATURE HEIGHTS FUNERAL HOME	
23d. LOCATION (City, town, or county) (State) Houston Texas		25c. REGISTRAR'S SIGNATURE	
25a. REGISTRAR'S FILE NO.		25b. DATE REC'D BY LOCAL REGISTRAR	

TEXAS DEPARTMENT OF HEALTH — BUREAU OF VITAL STATISTICS

MEDICAL CERTIFICATION

VS-112, REV. 1/58

854
2965

JOSEPH A. JACHIMCZYK, M.D., J.D.

FORENSIC PATHOLOGIST

ATTORNEY AT LAW

CHIEF MEDICAL EXAMINER



228-8311

EXT. 671 (DAY)


EXT. 212 (NIGHT)


OFFICE OF THE MEDICAL EXAMINER
OF HARRIS COUNTY

HARRIS COUNTY COURT HOUSE
HOUSTON, TEXAS 77002

September 27, 1973

This date, September 27, 1973, James A. Zotter, Chemist and Toxicologist, Houston Police Department, received head hair and pubic hair from Case 73 - 3329, Dean Arnold Corll, hair samples (head) from Cases 73 - 3333, 73 - 3334 and 73 - 3335, and samples of both types of cord which was recovered.


James A. Zotter


Joseph A. Jachimczyk, M.D., J.D.
Chief Medical Examiner

copy

BODY CAN BE VIEWED: YES _____ NO _____

SEX: M

RACE: W

EST. AGE: _____

HEIGHT: 72

WEIGHT: _____

EYES: _____

HAIR: It, brown 7 inches

SCARS: Decomposed body

TATTOOS: _____

OTHER: _____

X-RAY: _____

CLOTHING: Nude

PERSONAL EFFECTS: None

DECEDENT'S NAME: _____

DECEDENT'S ADDRESS: _____

NEXT OF KIN: _____

ADDRESS: _____

IDENTIFIED BY: _____ DATE: _____

ADDRESS: _____

HCME OFFICER PRESENT: _____

(13) 9-27-73 HPS Chemist + Toxicologist, James A.
Zotter rec'd head + pubic hair from dec.
Also rec'd. samples of both types of cord
that was recovered.

(13) 9-27-73 NPS Chemist & Toxicologist, James A.
Zotter rec'd head & pubic hair from dec.
Also rec'd. samples of both types of cord
that was recovered.

INVESTIGATOR'S REPORT

Autopsy

Investigator: L. C. Kelly

~~XXXXX~~

Case No. 73 - 3333

Decedent: Michael Anthony Baulch Race W Sex M Age 15

Address: 439 West 16th Street, Houston, Texas

Death: FOUND August 8, 1973 Approx. Time 8:00 ~~XXXXX~~
P.M.

Place of Death: 4500 Silverbell Street, Stall #11, Houston, Texas

Place of Inquest: 4500 Silverbell Street, Stall #11, Houston, Texas

Date and Time of Inquest: August 8, 1973 8:45 ~~XXXXX~~
P.M.

Location, Position, and Surroundings of Body:

The decedent was lying in grave #1, wrapped in plastic, lying on the left side under Unknown #1.

Clothing: There was no clothing.

Information:

This is a related case to Medicolegal 73-3329.

L. C. Kelly
L. C. Kelly *nn*

(See Companion Cases 73-3332, 73-3334, 73-3335, 73-3336, 73-3337, 73-3338, 73-3339, 73-3347, 73-3348, 73-3349, 73-3350, 73-3353, 73-3354, 73-3355, 73-3356 and 73-3357)

Property: There was no property.

Transferred to Morgue by: Bob Lee Funeral Home, Houston, Texas

Funeral Home Conducting Service: Heights Funeral Home, Houston, Texas

LOCATION: 4500 Silverbell ^{Stall # 11} GRAVE # 1
UNKNOWN # 2 M.E. CASE # 73-3333

IDENTIFIED
NAME: Michael Anthony Baulech
STILL UNKNOWN

I N V E N T O R Y S H E E T

HAIR SAMPLES: _____	AUTOPSY REPORT: ROUGH	<u>FINAL</u>
BODY X-RAYS: HCME <u>6</u> OTHER _____	SUPPLEMENTAL: ROUGH	<u>FINAL</u>
DENTAL X-RAYS: HCME _____ OTHER _____	INVESTIGATORS REPORT: ROUGH	FINAL
HCME PHOTOS: BODY _____ PERSONAL EFFECTS _____	SUPPLEMENTAL: ROUGH	FINAL
CLOTHING _____ DENTAL _____	TOXICOLOGY REPORT	
PHOTO FROM FAMILY: _____	DENTAL EXAMINATION: ROUGH	<u>FINAL FORM</u>
MISSING PERSONS REPORT _____	POINTS OF COMPARISON: ROUGH	FINAL FORM
DEATH CERTIFICATE <u>✓</u>	HCME DENTAL CHART _____	
BRIEF PHYSICAL DESCRIPTION <u>✓</u>	OTHER DENTAL CHART _____	
SYNOPSIS OF MEDICAL TESTIMONY: _____	EVIDENCE SHEET: _____	
CORRESPONDENCE: _____		

COMPARISONS: _____

OTHER: _____

STATE HIGHWAY PATROL

DENTAL CHART

Fill out all information in PENCIL

_____ Assigned identification number	_____ Division Case Number
<u>73-3333 #2</u> Autopsy number	_____ Picture Pouch Number
_____ Armed Forces Serial Number	<u>8/10/73</u> Date of Exam.
_____ Social Security Number	_____ Place of Exam.

IDENTIFICATION STATUS (CIRCLE ONE)

UNIDENTIFIED AT PRESENT TIME, PRESUMPTIVE BY EXCLUSION, HIGHLY PROBABLE, POSITIVE

<i>Michael Baulch</i>			
Name of Person Identified	Age	Race	Sex

The above block is to be completed after all I.D. Procedures are exhausted.

CONFIRMED IDENTIFICATION OF BODY BY _____
Name of Examiner

Confirmed identification by means of (circle) X-ray comparison, Clinical conformation by previous dental records, Other _____

X-rays taken (circle one) None, Complete Mouth, Bite Wings, Other _____

Photographs taken (circle one) None, Color, Black & White, Other _____

Name, Address, and Telephone Number of Photographer

Location of the Body

Position of the Body

<p>BEFORE PROCEEDING—READ PAGE 2 CAREFULLY AND FOLLOW ALL INSTRUCTIONS—HAVE A QUALIFIED ASSISTANT TO DO ALL RECORDING RECORD ALL INFORMATION IN PENCIL</p>
--

Name, Address, and Telephone Number of the Examiner

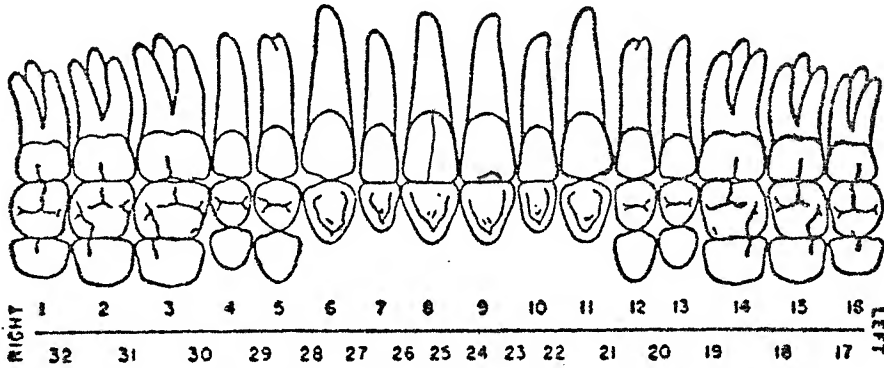
Name, Address, and Telephone Number of the Assistant

Signature of the examiner

Signature of the Assistant

MARK ALL EXISTING RESTORATIONS AND MISSING TEETH ON THIS CHART

Estimated Age _____
 Sex _____
 Race _____



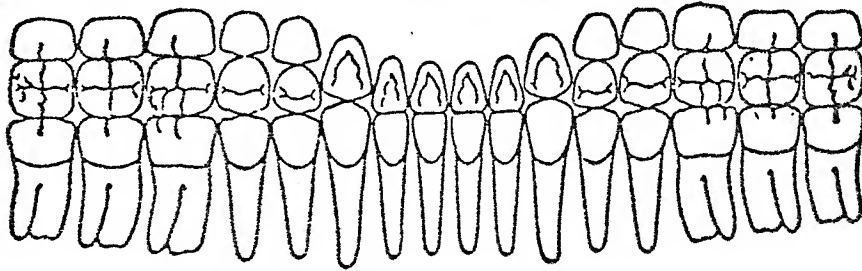
Circle descriptive term

Prosthetic Appliances Present — Maxilla

Full Denture

Partial Denture

Fixed Bridge



Prosthetic Appliances Present — Mandible

Full Denture

Partial Denture

Fixed Bridge

Describe completely all Prosthetic Appliances or

Fixed Bridges # 9 CHIPPED INCISAL # 8 VERTICAL CRACK

Stains on teeth

Slight

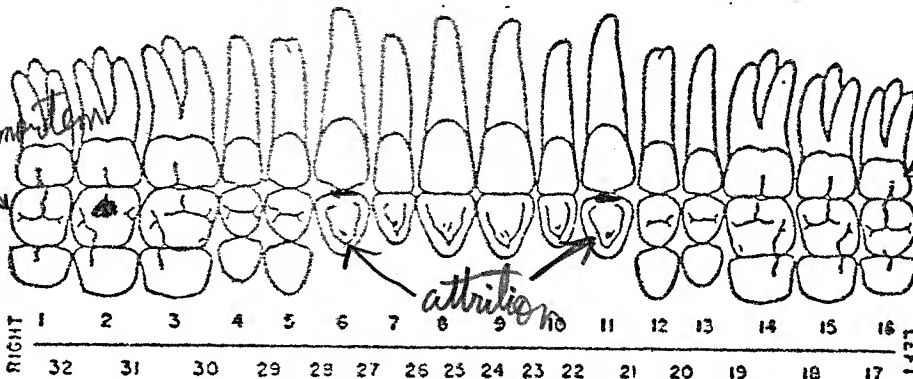
Moderate

Severe

MARK ALL CARIES

TEETH ON THIS CHART

Outline all caries and 'X' out all missing teeth



Circle descriptive term

Jaw Relationship

Normal

Undershot

Overbite

Periodontal condition

Excellent

Average

Poor


Gross Neglect

Calculus

Slight

Moderate

Severe



JOSEPH A. JACHIMCZYK, M.D., J.D.
FORENSIC PATHOLOGIST
ATTORNEY AT LAW
CHIEF MEDICAL EXAMINER




228-8311
EXT. 671 (DAY)
EXT. 212 (NIGHT)


OFFICE OF THE MEDICAL EXAMINER
OF HARRIS COUNTY

HARRIS COUNTY COURT HOUSE
HOUSTON, TEXAS 77002

September 27, 1973

This date, September 27, 1973, James A. Zotter, Chemist and Toxicologist, Houston Police Department, received head hair and pubic hair from Case 73 - 3329, Dean Arnold Corll, hair samples (head) from Cases 73 - 3333, 73 - 3334 and 73 - 3335, and samples of both types of cord which was recovered.


James A. Zotter


Joseph A. Jachimczyk, M.D., J.D.
Chief Medical Examiner

1973 MASS MURDER INVENTORY CASES TO DATE AS OF 071501

DR. DELATTRE VIEWED CASE: _____ CASE FINDINGS...SEE ATTACHED REPORT DATED _____

ITEM #	CASE #	DECEDENT'S NAME	TYPE OF REMAINS	LOCATION OF REMAINS	DATE FOUND	DATE ID'D & BY	WHAT METHOD
(2)	73-3333	Michael Anthony Baulch	W/M/age?	See Autopsy Report	8-8-73	10-9-73	See Supplement
FOUND@:		4500 Silverbell St. Stall #11, Grave #1			Boatshed		ID Made by parents
NOK NOTIFIED:		(Y)/N			Decomp		Viewing dentals, Clothing, photo positive comparison
DATE /TIME NOTIFIED:		10-9-73 Time (N/A)		NOTIFIED BY WHOM:		See 10/9/73 Supplement	
AUTOPSY DONE BY/DATE:		Dr. Sachimczyk		8-9-73			
INVESTIGATOR REPORT:		(Y)/N		AUTOPSY REPORT:		(Y)/N	
POLICE REPORT:		Y/(N)		SCENE PHOTOS:		Y/(N)	
DEATH CERTIFICATE:		(Y)/N		DATE D/C SIGNED:		10-17-73 - Billy Baulch, Sr Dad	

FULL BODY XRAYS:	(Y)/N	DENTAL CHART/XRAYS:	Y/(N)	DNA:	(Y)/N	RELEASE SIGNED:	Y/(N)
@ autopsy		See Autopsy Exam Done		9-27-73 letter		DATE:	Not in file
Skeletal remains		By Dr. P.G. Stimson		Head/Pubic Hair		BY:	

TRANSFERRED TO HCME BY: Bob Lee FH

FUNERAL HOME: Heights

BURIED Woodlawn CREMATED Garden of memories

MANNER OF DEATH: GSW (3) of head

DOD: 8-21-73/autopsy report

SOURCE: HCME Records Dept + Investigator File

OTHER

INFORMATION: No clothing, other than belt buckle

Compasses: 73-3332, 3334, 3335, 3336, 3337, 3338, 3339, 3347, 3348, 3349, 3350, 3353, 3354, 3355, 3356, 3357